

A Truncating Mutation of *TRAPPC9* Is Associated with Autosomal-Recessive Intellectual Disability and Postnatal Microcephaly

Ganeshwaran H. Mochida,^{1,2,3,4} Muhammad Mahajnah,^{5,6} Anthony D. Hill,^{1,2} Lina Basel-Vanagaite,^{7,9,10} Danielle Gleason,³ R. Sean Hill,^{1,2} Adria Bodell,^{1,2} Moira Crosier,¹¹ Rachel Straussberg,^{8,10} and Christopher A. Walsh^{1,2,3,*}

Although autosomal genes are increasingly recognized as important causes of intellectual disability, very few of them are known. We identified a genetic locus for autosomal-recessive nonsyndromic intellectual disability associated with variable postnatal microcephaly through homozygosity mapping of a consanguineous Israeli Arab family. Sequence analysis of genes in the candidate interval identified a nonsense nucleotide change in the gene that encodes *TRAPPC9* (trafficking protein particle complex 9, also known as NIBP), which has been implicated in NF- κ B activation and possibly in intracellular protein trafficking. *TRAPPC9* is highly expressed in the postmitotic neurons of the cerebral cortex, and MRI analysis of affected patients shows defects in axonal connectivity. This suggests essential roles of *TRAPPC9* in human brain development, possibly through its effect on NF- κ B activation and protein trafficking in the postmitotic neurons of the cerebral cortex.

Intellectual disability (ID), also referred to as mental retardation, is a major public health issue, affecting more than 1% of children worldwide,¹ yet the specific causes of ID are often not identified. ID can be observed as part of broader syndromes affecting other organs (e.g., Down syndrome) or in isolation without other organ involvement. When the brain is the only affected organ, it could be structurally abnormal, such as with lissencephaly, or grossly normal (nonsyndromic ID or nonsyndromic MR). So far, the studies of nonsyndromic ID have mostly focused on its X-linked recessive forms. Over 80 genes associated with ID on the X chromosome have been identified, and among them, about 30 cause nonsyndromic ID.² Many of these causative genes have been found to function in synapses.³ However, the X chromosome represents only about 5% of our genome,⁴ and there is increasing evidence to suggest that there are many autosomal-recessive loci for nonsyndromic ID. There has been a report suggesting at least eight autosomal-recessive loci for nonsyndromic ID.⁵ Moreover, only 25% of families with ID and pedigree structures suggesting X-linked inheritance were found to have pathogenic mutations in a recent large-scale screen of the coding exons of the X chromosome.⁶ This suggests that autosomal-recessive ID might be relatively common in familial ID even when the pedigree structure is compatible with X-linked inheritance. Despite this, so far only five autosomal-recessive genes have been identified: *PRSS12* (MIM 606709),⁷ *CRBN* (MIM 609262),⁸ *CC2D1A* (MIM

610055),⁹ *GRIK2* (MIM 138244),¹⁰ and *TUSC3* (MIM 601385).^{11,12} This is probably due to the fact that the “nonsyndromic” nature of the condition makes it difficult to pool multiple pedigrees with the same underlying genetic defects to achieve statistical significance.

Causative genes for nonsyndromic ID are involved in many biological processes and offer critical insights into the genetic basis of human cognitive function. Many X-linked nonsyndromic ID genes are implicated in synaptogenesis and synaptic transmission.³ In addition, *SYNGAP1*, which is associated with autosomal dominant nonsyndromic ID, encodes a ras GTPase-activating protein, a component of the NMDA-receptor complex.¹³ The functions of the autosomal-recessive nonsyndromic ID genes are less well understood, but they appear to be quite diverse. It has been shown that *PRSS12* localizes to presynaptic nerve endings of cortical synapses,⁷ *CRBN* might regulate mitochondrial energy metabolism,⁸ *CC2D1A* has been implicated in NF- κ B signaling,^{9,14} *GRIK2* is a neurotransmitter receptor,¹⁰ and *TUSC3* might be a subunit of an oligosaccharyltransferase.^{11,12} Thus, no consistent picture has yet emerged of a major biochemical pathway, though further gene identification might provide that.

We identified an Israeli Arab pedigree in which three girls are affected with moderate to severe ID and variable postnatal microcephaly. The parents were second cousins once removed, and there were no unaffected siblings. All

¹Department of Neurology, ²Howard Hughes Medical Institute, Beth Israel Deaconess Medical Center, Harvard Medical School, Boston, MA 02115, USA; ³Division of Genetics and Manton Center for Orphan Disease Research, Department of Medicine, Children's Hospital Boston, Boston, MA 02115, USA; ⁴Pediatric Neurology Unit, Department of Neurology, Massachusetts General Hospital, Boston, MA 02114, USA; ⁵Pediatric Neurology and Child Developmental Center, Hillel Yaffe Medical Center, Hadera 38100, Israel; ⁶Rappaport Faculty of Medicine, The Technion, Haifa 31096, Israel; ⁷Department of Medical Genetics, ⁸Neurogenetic Clinic, Schneider Children's Medical Center of Israel, Petah Tikva 49202, Israel; ⁹Raphael Recanati Genetics Institute, Rabin Medical Center, Beilinson Campus, Petah Tikva 49202, Israel; ¹⁰Sackler Faculty of Medicine, Tel Aviv University, Tel Aviv 69978, Israel; ¹¹MRC-Wellcome Trust Human Developmental Biology Resource (Newcastle), Institute of Human Genetics, Newcastle University, International Centre for Life, Newcastle upon Tyne NE1 3BZ, UK

*Correspondence: christopher.walsh@childrens.harvard.edu

DOI 10.1016/j.ajhg.2009.10.027. ©2009 by The American Society of Human Genetics. All rights reserved.

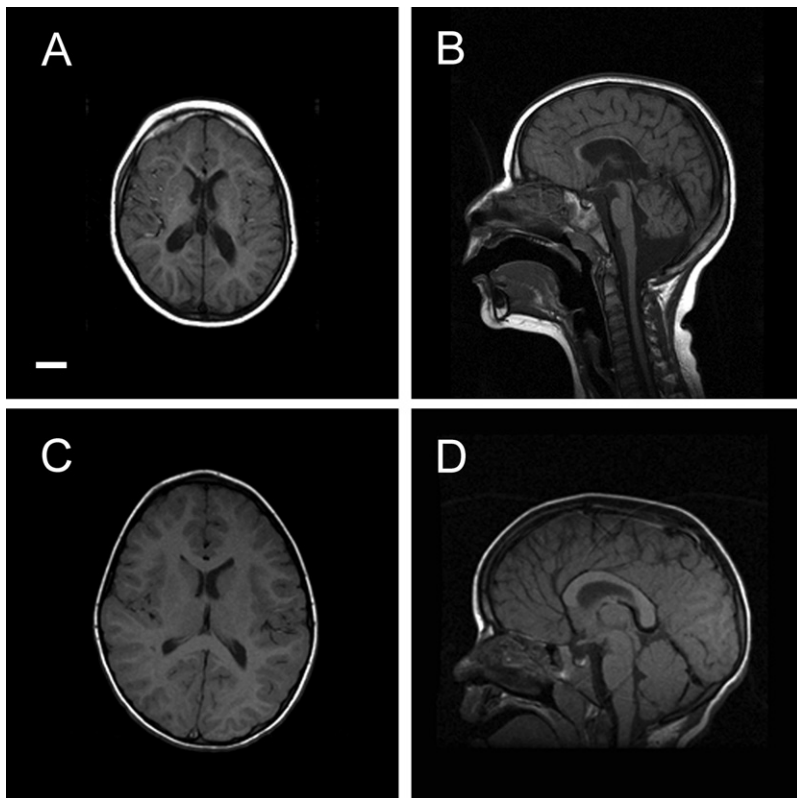


Figure 1. Brain MRI of a Patient with a *TRAPPC9* Mutation

(A) T1-weighted axial image of Patient 2 (MC-6102) reveals microcephaly but a normal gyral pattern of the cerebral cortex. The cerebral white matter is reduced. Scale bar is 2 cm for all images. (B) T1-weighted sagittal image of the same patient is remarkable for a thin but fully formed corpus callosum and mild hypoplasia of the inferior cerebellar vermis. (C) T1-weighted axial image of an age-matched control individual. (D) T1-weighted sagittal image of an age-matched control individual.

three patients had unremarkable prenatal and perinatal histories and were delivered at term. Patient 1 (MC-6101) was 7 years and 10 months old at the time of examination. Her head circumference at birth was 32 cm (-1.3 SD) and most recently was 46.2 cm (-4.1 SD). She had severe cognitive delay, and her language was limited to only a few single words. She was totally dependent on others for the tasks of daily living and showed bruxism and hand-flapping movements. However, she had normal motor development and did not have any difficulty in ambulation. She had no spasticity, and except for equivocal plantar responses, her neurological examination was normal. Her karyotype was normal. At ages 2 and 4 years, she underwent brain MRI examinations, which were remarkable for a thin corpus callosum and reduced volume of the cerebral white matter. There was no evidence of cortical dysplasia. Patient 2 (MC-6102) was examined at age 4 years and 8 months. Her head circumference at birth was 33.5 cm (-0.3 SD) and most recently was 46.2 cm (-3.3 SD). Her cognition was moderately delayed. She was able to say a few words and recognized body parts. Her motor development was normal, and her neurological examination was normal. Her brain MRI also showed a thin but fully formed corpus callosum and moderately to severely reduced volume of the cerebral white matter, but no abnormalities involving the cerebral cortical gray matter were seen (Figure 1). There was hypoplasia of the inferior cerebellar vermis. There were no signal abnormalities in the cerebral gray and white matter. Patient 3 (MC-6103) was 2 years and 10 months of age at the time of examination.

Her head circumference at birth was 31 cm (-2.0 SD) and most recently was 42.2 cm (-5.8 SD). Her cognitive function was in the range of moderate ID. None of the patients had facial or somatic dysmorphic features or clinical involvement of organs other than the CNS. Also, none of the patients had autistic features or epilepsy. There was no evidence of developmental regression in any of the patients.

We collected peripheral blood samples from the affected children and parents after informed consent was obtained according

to the protocols approved by the participating institutions. All the research procedures followed were in accordance with the ethical standards of the responsible national and institutional committees on human subject research. Genome-wide microsatellite screening using extracted DNA was performed at the Center for Inherited Disease Research (Baltimore, MD). A total of 405 markers with an average spacing of 9 cM were used. There was no gap greater than 20 cM. LOD score was calculated using Allegro¹⁵ from the genome-wide microsatellite screening data, assuming an autosomal-recessive mode of inheritance with 100% penetrance and a disease allele prevalence of 0.001. This identified three regions (22q, 8q, and 2p) with a LOD score between 2.5 and 3.0 (see Table S1 available online). Additional microsatellite marker analysis of these three regions, however, determined that only one, the chromosome 8q locus, was likely to represent a true region of identity by descent. The candidate interval was defined by the recombinant markers D8S272 and D8S1744 and was 12.02 cM in size (Figure 2A). A maximum multipoint LOD score of 3.26 was obtained within this region, using the same parameters as above (Figure 2B). A total of 13 RefSeq (NCBI reference sequences collection) genes within this interval were identified from UCSC Genome Browser, and we initially selected 6 genes for sequencing, based mainly on the evidence of expression in the fetal or infantile brain according to UniGene (Table S2). Coding exons of these genes were sequenced in one of the affected individuals, and a homozygous nucleotide change (from C to T) in the exon 7 of the

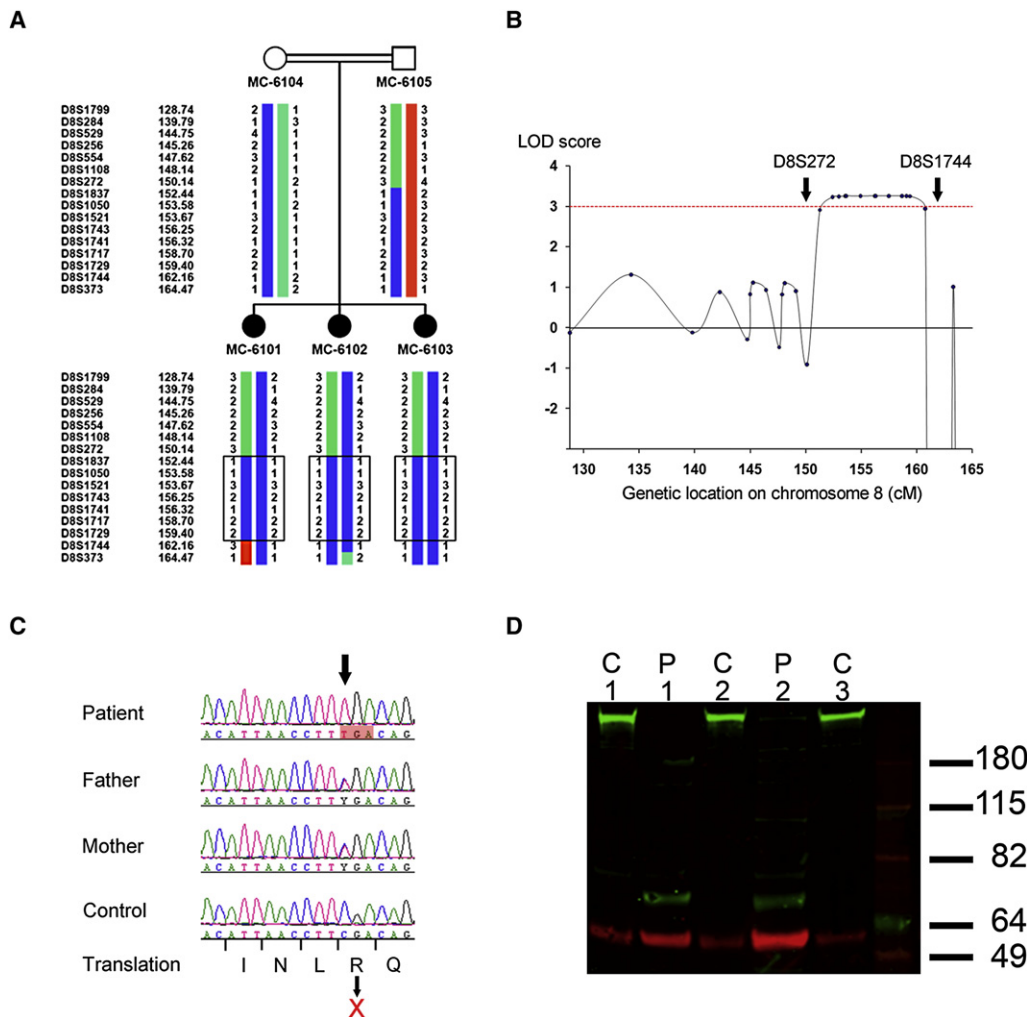


Figure 2. Mapping and Cloning of the Causative Gene

(A) Pedigree and haplotype of the distal chromosome 8 of the family studied. There is an area of shared homozygosity in all three affected children (box). This identified the candidate region as defined by markers D8S272 and D8S1744.

(B) A graph showing multipoint LOD scores of the same region of chromosome 8. LOD scores above 3.0 were achieved between D8S272 and D8S1744.

(C) Sequencing of candidate genes within the interval revealed a nonsense nucleotide change in the exon 7 of the *TRAPPC9* gene. The C to T change (arrow) in patients creates a stop codon (red shaded box) and is expected to result in R to X change on the amino acid level.

(D) Western blot analysis of the lymphoblasts from the patients and control individuals. A single band was detected by Trappc9 antibody (green) in protein extracts from three different control lymphoblasts (C1, C2, and C3). This band was not detected in lymphoblast extracts from Patient 1 or Patient 2 (P1 and P2, respectively), despite the fact that a higher amount of protein was loaded compared to the control samples. Red represents a loading control (β -actin).

TRAPPC9 gene (MIM 611966) was identified (Figure 2C). This nucleotide change is predicted to convert an arginine to a premature stop codon. According to RefSeq, there are two transcript variants (1 and 2) of *TRAPPC9* in human. Variant 1 is the longer form and encodes 1246 amino acids. Variant 2, on the other hand, uses an alternate 5' exon and initiates translation at a downstream start codon, thereby encoding 1148 amino acids. The nucleotide change identified in this family is expected to affect both variants (c.1423C \rightarrow T [p.R475X] in variant 1 and c.1129C \rightarrow T [p.R377X] in variant 2). The same nucleotide change was identified in both other affected children, and both parents were heterozygous carriers. We sequenced this exon in a total of 153 normal control individuals (306

chromosomes), including 100 controls of European descent and 10 controls of Middle Eastern descent (Coriell Institute for Medical Research; Camden, NJ), as well as 43 additional unrelated Middle Eastern Arab normal controls we have collected, and none of these individuals had the same nucleotide change. Next, we developed an antibody against the peptide corresponding to a segment of the mouse Trappc9 protein (amino acids 483–497 of NP_850993; LDFLSDQEKKDVTQS). This peptide sequence is highly homologous to the corresponding region of the human TRAPPC9 protein, and the only difference is that the threonine (T) at position 13 of the peptide is occupied by an alanine (A) residue in human. Therefore, we felt it was likely that this antibody would recognize the human

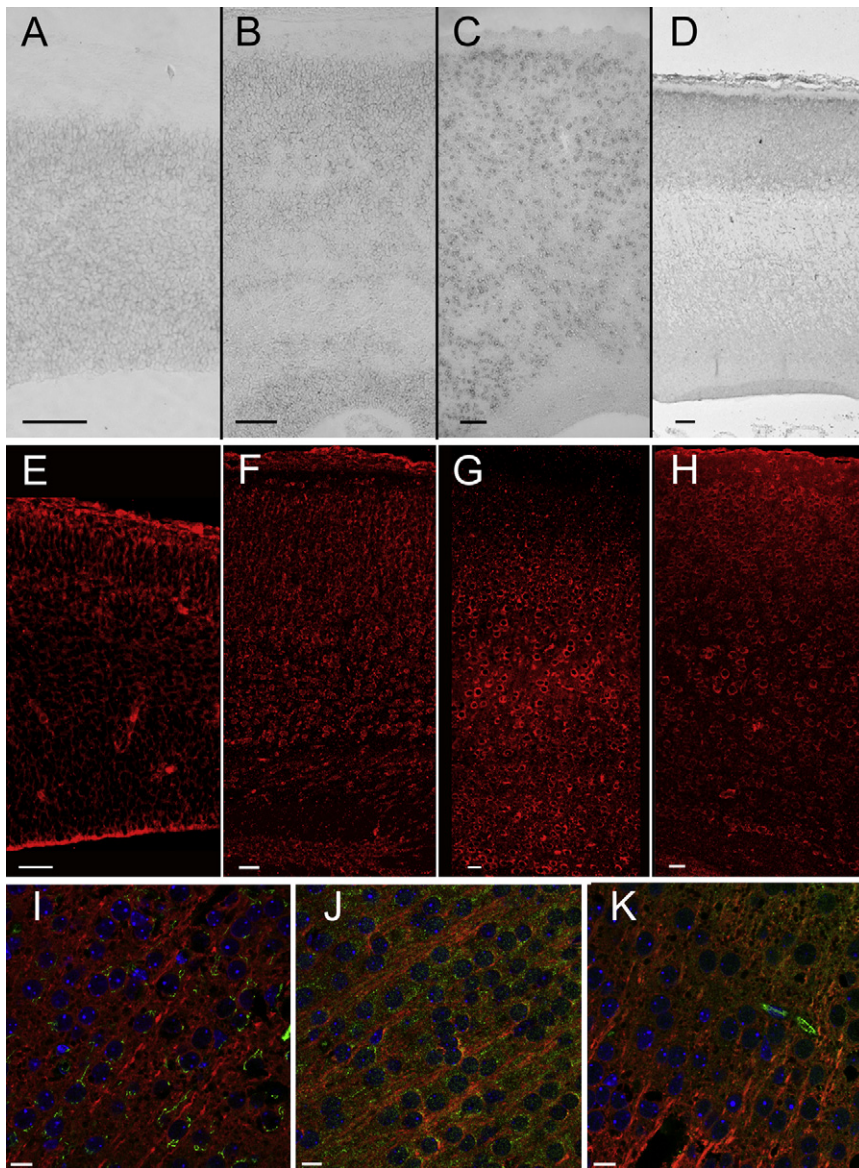


Figure 3. In Situ Hybridization and Immunofluorescence Studies of *TRAPPC9* in the Developing Mouse and Human Brain

(A) In E14 mouse brain, a low level of *Trappc9* RNA expression was seen throughout the cerebral mantle (scale bar in [A]–[H] = 100 μ m).

(B) In P0 mouse brain, there was a slightly higher level of RNA expression in the cerebral mantle, with the exception of the developing white matter, which is devoid of staining.

(C) In adult mouse cerebral cortex, there is a moderate to high level of RNA expression in cortical neurons of all layers.

(D) In human brain at 11.5 weeks, a moderate level of *TRAPPC9* RNA expression is seen in the cortical plate.

(E) In E15 mouse brain, *Trappc9* protein could be detected throughout the cerebral cortex, with increased accumulation in the cortical plate.

(F) In P3 mouse brain, *Trappc9* protein was detected in the cell bodies of cortical plate neurons and in cells within the subventricular zone.

(G) Neuronal accumulation of *Trappc9* continued in the P8 cerebral cortex, with higher levels of signal in the large pyramidal neurons of layer V.

(H) *Trappc9* immunofluorescence persisted in adult mouse cortical neurons.

(I) Confocal microscopy of mouse cortical plate revealed distinct subcellular locations for *Trappc9* (red) and the Golgi apparatus marker GM130 (green) (scale bar in [I]–[K] = 10 μ m).

(J) *Trappc9* (red) did not colocalize with Rab7 (green), a marker of late endosomes and lysosomes.

(K) *Trappc9* (red) did not colocalize with transferrin receptor (green), a marker for early endosomes.

TRAPPC9 protein, as well. We then established lymphoblast cell lines from two of the patients and performed western blot analysis of the TRAPPC9 protein using this antibody. The patient cell lines and control cell lines were established and processed using the same standard protocol under identical conditions. A single band was detected in control lysates. Interestingly, this band ran at a significantly higher apparent molecular mass (~250 kDa) than would be predicted by the TRAPPC9 sequence (~140 kDa), suggesting the possibility that TRAPPC9 undergoes extensive posttranslational modification. In lysates from the patients, this band was completely absent, confirming the absence of the wild-type TRAPPC9 protein in the patients' tissue (Figure 2D).

To understand the potential function of TRAPPC9 during development of the cerebral cortex, we analyzed the expression of the mRNA and protein. Nonradioactive in situ hybridization was performed as described,¹⁶ using a digoxigenin (DIG)-labeled cRNA probe that contained

895 bases of mouse *Trappc9* sequence (nucleotides 2341–3235 of NM_029640). In E14 mouse brain, low levels of expression were seen (Figure 3A). In P0, expression in the cerebral cortex (Figure 3B) as well as hippocampus (data not shown) was slightly higher than at E14, whereas in the adult brain, there is strong expression in neurons of the cerebral cortex (Figure 3C) as well as hippocampus and deep gray matter (data not shown). We also performed in situ hybridization using human embryonic brain (11.5 weeks) and cRNA probe that contained 898 bases of human *TRAPPC9* sequence (nucleotides 3118–4015 of NM_031466). This revealed a slightly higher level of expression in the developing cortical plate compared to the ventricular zone (Figure 3D), confirming the higher expression in postmitotic neurons than in progenitor cells. Immunofluorescent analysis of the developing mouse brain (using the same antibody used for the western blot analysis) revealed a pattern of *Trappc9* protein accumulation that is consistent with the in situ hybridization data.

Trappc9 protein was detected throughout the cerebral cortex at E15, P3, and P8 and in adult (Figures 3E–3H), with particularly high levels of signal in postmitotic neurons. High magnification and confocal imaging suggested that Trappc9 immunoreactivity is widespread in the cytoplasm, without specific localization to any particular organelle. Specifically, no clear colocalization was observed between Trappc9 and protein markers for Golgi apparatus, late endosomes, or early endosomes (Figures 3I–3K). No evidence of nuclear localization was seen. The data suggest that Trappc9 has important roles in the cytoplasm of postmitotic neurons.

TRAPPC9 was originally identified in a yeast two-hybrid analysis as a binding partner of NF- κ B-inducing kinase (NIK),¹⁷ and it is also known as NIBP (NIK- and IKK- β -binding protein). TRAPPC9 has been shown to enhance TNF α -induced NF- κ B activation; also, siRNA-mediated knockdown showed impairment of nerve growth factor-induced neuronal differentiation of PC12 cells as measured by neurite extension.¹⁷ Thus, it appears that TRAPPC9 is a positive regulator of NF- κ B, at least in vitro. NF- κ B signaling is involved in a wide range of biological processes, including inflammation, immunity, and synaptic plasticity, and it has also been suggested to regulate adult neurogenesis.^{18–20} However, the role of NF- κ B signaling in the human brain is not well understood. Interestingly, another gene product associated with autosomal-recessive nonsyndromic ID, CC2D1A, was also originally identified as a positive regulator of the NF- κ B signaling pathway.¹⁴ This further suggests a potential role of NF- κ B signaling in neuronal function and suggests potential relationships between CC2D1A and TRAPPC9 function.

Another potential clue as to the functions of TRAPPC9 comes from its conserved domain structure. The amino acids 704–986 of the TRAPPC9 protein isoform “a” (which is encoded by the transcript variant 1) represent a Trs120 domain (InterPro accession number IPR013935; Pfam ID PF08626), whose prototype is the yeast protein Trs120. Trs120 is a subunit of the multiprotein complex TRAPP (transport protein particle), and mutants in Trs120 have been shown to disrupt traffic from the early endosome to the late Golgi.²¹ To our knowledge, TRAPPC9 is the only known human protein with the Trs120 domain and therefore might represent the human ortholog of the yeast Trs120 protein.

The expression pattern of *TRAPPC9*, the abnormal MRI pattern, and the normal head circumference at birth all suggest that TRAPPC9 has its essential function in postmitotic neurons as opposed to neural progenitors. In contrast to patients with the *TRAPPC9* mutation, patients with primary autosomal-recessive microcephaly, whose causative genes seem to regulate cell division of neural progenitors, show significantly small head circumference already at the time of birth.²² The brain MRI findings of the patients are rather nonspecific, but the most striking feature is reduced volume of the cerebral white matter and corpus callosum, which usually reflects abnormal

axon and/or dendrite outgrowth rather than a reduced number of neurons. This hypothesis is consistent with our expression data showing highest level of expression in postmitotic neurons and with data that showed TRAPPC9 regulates nerve growth factor-induced neurite extension.¹⁷ Abnormal axon and/or dendrite outgrowth also likely explains the variable degree of postnatal microcephaly observed in this family. Further elucidation of the functions of TRAPPC9 in the neurons of the cerebral cortex and its potential relationships to CC2D1A and NF- κ B function could lead to a better understanding of molecular mechanisms of human cognitive function.

Supplemental Data

Supplemental Data include two tables and can be found with this article online at <http://www.cell.com/AJHG>.

Acknowledgments

We would like to thank the patients and family for their participation in this research. Genotyping services were provided by the Center for Inherited Disease Research (CIDR). CIDR is fully funded through a federal contract from the National Institutes of Health to The Johns Hopkins University, contract number HHSN268200782096C. We thank Jennifer Partlow and Brenda Barry for coordinating patient studies, James Barkovich for help in interpretation of brain MRI of Patient 2, Jillian Felie and Dan Rakec for technical assistance in DNA sequencing, the Partners HealthCare Center for Personalized Genetic Medicine for establishing the lymphoblast cell lines, and Urs Berger for help with in situ hybridization using the mouse brain. The authors would like to thank Jacques Michaud for sharing DNA samples. The human embryonic and fetal material was provided by the joint MRC-Wellcome Trust Human Developmental Biology Resource at the Institute of Human Genetics, Newcastle-upon-Tyne, UK. We thank the consenting women who made this study possible and A. Farnworth, who gained consent on our behalf. This research was supported by grants from the NINDS (2R01NS035129-12) to C.A.W. and by the Nancy Lurie Marks Family Foundation, the Dubai Harvard Foundation for Medical Research, the Simons Foundation, and the Manton Center for Orphan Disease Research. G.H.M. was supported by the Young Investigator Award of NARSAD as a NARSAD Lieber Investigator. C.A.W. is an Investigator of the Howard Hughes Medical Institute.

Received: September 12, 2009

Revised: October 22, 2009

Accepted: October 26, 2009

Published: December 10, 2009

Web Resources

The URLs for data presented herein are as follows:

InterPro, <http://www.ebi.ac.uk/interpro/>

MRC-Wellcome Trust Human Developmental Biology Resource, <http://www.hdbr.org>

NCBI Reference Sequence (RefSeq), <http://www.ncbi.nlm.nih.gov/RefSeq/>

Online Mendelian Inheritance in Man (OMIM), <http://www.ncbi.nlm.nih.gov/Omim/>
Pfam, <http://pfam.sanger.ac.uk/>
UCSC Genome Browser, <http://genome.ucsc.edu/>
UniGene, <http://www.ncbi.nlm.nih.gov/unigene>

References

1. WHO (2001). Mental health: new understanding, new hope. In World Health Report 2001, R.S. Murthy, ed. (Geneva: World Health Organization), pp. 35.
2. Ropers, H.H. (2008). Genetics of intellectual disability. *Curr. Opin. Genet. Dev.* 18, 241–250.
3. Ropers, H.H. (2006). X-linked mental retardation: many genes for a complex disorder. *Curr. Opin. Genet. Dev.* 16, 260–269.
4. Ross, M.T., Grafham, D.V., Coffey, A.J., Scherer, S., McLay, K., Muzny, D., Platzer, M., Howell, G.R., Burrows, C., Bird, C.P., et al. (2005). The DNA sequence of the human X chromosome. *Nature* 434, 325–337.
5. Najmabadi, H., Motazacker, M.M., Garshasbi, M., Kahrizi, K., Tzschach, A., Chen, W., Behjati, F., Hadavi, V., Nieh, S.E., Abedini, S.S., et al. (2007). Homozygosity mapping in consanguineous families reveals extreme heterogeneity of nonsyndromic autosomal recessive mental retardation and identifies 8 novel gene loci. *Hum. Genet.* 121, 43–48.
6. Tarpey, P.S., Smith, R., Pleasance, E., Whibley, A., Edkins, S., Hardy, C., O'Meara, S., Latimer, C., Dicks, E., Menzies, A., et al. (2009). A systematic, large-scale resequencing screen of X-chromosome coding exons in mental retardation. *Nat. Genet.* 41, 535–543.
7. Molinari, F., Rio, M., Meskenaite, V., Encha-Razavi, F., Augé, J., Bacq, D., Briault, S., Vekemans, M., Munnich, A., Attié-Bitach, T., et al. (2002). Truncating neurotrophin mutation in autosomal recessive nonsyndromic mental retardation. *Science* 298, 1779–1781.
8. Higgins, J.J., Pucilowska, J., Lombardi, R.Q., and Rooney, J.P. (2004). A mutation in a novel ATP-dependent Lon protease gene in a kindred with mild mental retardation. *Neurology* 63, 1927–1931.
9. Basel-Vanagaite, L., Attia, R., Yahav, M., Ferland, R.J., Anteki, L., Walsh, C.A., Olender, T., Straussberg, R., Magal, N., Taub, E., et al. (2006). The CC2D1A, a member of a new gene family with C2 domains, is involved in autosomal recessive nonsyndromic mental retardation. *J. Med. Genet.* 43, 203–210.
10. Motazacker, M.M., Rost, B.R., Hucho, T., Garshasbi, M., Kahrizi, K., Ullmann, R., Abedini, S.S., Nieh, S.E., Amini, S.H., Goswami, C., et al. (2007). A defect in the ionotropic glutamate receptor 6 gene (GRIK2) is associated with autosomal recessive mental retardation. *Am. J. Hum. Genet.* 81, 792–798.
11. Garshasbi, M., Hadavi, V., Habibi, H., Kahrizi, K., Kariminejad, R., Behjati, F., Tzschach, A., Najmabadi, H., Ropers, H.H., and Kuss, A.W. (2008). A defect in the TUSC3 gene is associated with autosomal recessive mental retardation. *Am. J. Hum. Genet.* 82, 1158–1164.
12. Molinari, F., Foulquier, F., Tarpey, P.S., Morelle, W., Boissel, S., Teague, J., Edkins, S., Futreal, P.A., Stratton, M.R., Turner, G., et al. (2008). Oligosaccharyltransferase-subunit mutations in nonsyndromic mental retardation. *Am. J. Hum. Genet.* 82, 1150–1157.
13. Hamdan, F.F., Gauthier, J., Spiegelman, D., Noreau, A., Yang, Y., Pellerin, S., Dobrzyniecka, S., Côté, M., Perreault-Linck, E., Carmant, L., et al. (2009). Mutations in SYNGAP1 in autosomal nonsyndromic mental retardation. *N. Engl. J. Med.* 360, 599–605.
14. Matsuda, A., Suzuki, Y., Honda, G., Muramatsu, S., Matsuzaki, O., Nagano, Y., Doi, T., Shimotohno, K., Harada, T., Nishida, E., et al. (2003). Large-scale identification and characterization of human genes that activate NF- κ B and MAPK signaling pathways. *Oncogene* 22, 3307–3318.
15. Gudbjartsson, D.F., Thorvaldsson, T., Kong, A., Gunnarsson, G., and Ingólfssdóttir, A. (2005). Allegro version 2. *Nat. Genet.* 37, 1015–1016.
16. Berger, U.V., and Hediger, M.A. (2001). Differential distribution of the glutamate transporters GLT-1 and GLAST in tanycytes of the third ventricle. *J. Comp. Neurol.* 433, 101–114.
17. Hu, W.H., Pendergast, J.S., Mo, X.M., Brambilla, R., Bracchi-Ricard, V., Li, F., Walters, W.M., Blits, B., He, L., Schaaf, S.M., et al. (2005). NIBP, a novel NIK and IKK(β)-binding protein that enhances NF-(κ)B activation. *J. Biol. Chem.* 280, 29233–29241.
18. Denis-Donini, S., Dellarole, A., Crociara, P., Francese, M.T., Bortolotto, V., Quadrato, G., Canonico, P.L., Orsetti, M., Ghi, P., Memo, M., et al. (2008). Impaired adult neurogenesis associated with short-term memory defects in NF- κ B p50-deficient mice. *J. Neurosci.* 28, 3911–3919.
19. Rolls, A., Shechter, R., London, A., Ziv, Y., Ronen, A., Levy, R., and Schwartz, M. (2007). Toll-like receptors modulate adult hippocampal neurogenesis. *Nat. Cell Biol.* 9, 1081–1088.
20. Widera, D., Mikenberg, I., Elvers, M., Kaltschmidt, C., and Kaltschmidt, B. (2006). Tumor necrosis factor alpha triggers proliferation of adult neural stem cells via IKK/NF- κ B signaling. *BMC Neurosci.* 7, 64.
21. Cai, H., Zhang, Y., Pypaert, M., Walker, L., and Ferro-Novick, S. (2005). Mutants in trs120 disrupt traffic from the early endosome to the late Golgi. *J. Cell Biol.* 171, 823–833.
22. Mochida, G.H., and Walsh, C.A. (2001). Molecular genetics of human microcephaly. *Curr. Opin. Neurol.* 14, 151–156.